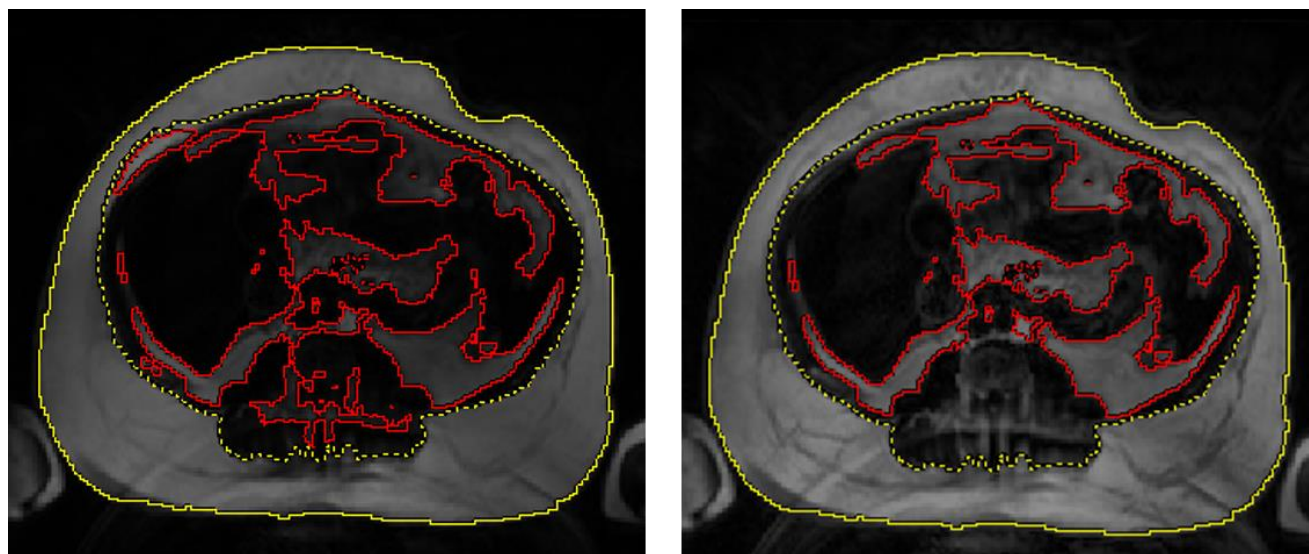


SUPPLEMENTARY DATA

Alzheimer Disease Pathology and Neurodegeneration in Midlife Obesity: A Pilot Study

**Mahsa Dolatshahi, Paul K. Commean, Farzaneh Rahmani, Jingxia Liu, LaKisha Lloyd, Caitlyn
Nguyen, Nancy Hantler, Maria Ly, Gary Yu, Joseph E. Ippolito, Claude Sirlin, John C. Morris,
Tammie L.S. Benzinger, Cyrus A. Raji**

SUPPLEMENTARY DATA



Supplementary Figure 1. After automatic segmentation of subcutaneous and visceral fat by Voxa (left), the segmentations were inspected and manually edited, including manual removal of fat in the spinal region (right).

Supplementary Table 1. Cortical signature FreeSurfer regions in autosomal dominant and late onset AD.

ADAD Cortical Signature, Right Hemisphere	ADAD Cortical Signature, Left Hemisphere	LOAD Cortical Signature, Right Hemisphere	LOAD Cortical Signature, Left Hemisphere
inferior parietal	precuneus	entorhinal	entorhinal
bankssts	isthmus cingulate	temporal pole	middle temporal
precuneus		middle temporal	superior temporal
superior parietal		parahippocampal	temporal pole
lateral occipital		precuneus	bankssts
		superior temporal	medial orbital frontal
		fusiform	transverse temporal
		inferior parietal	precuneus
		bankssts	
		supramarginal	
		inferior temporal	
		superior parietal	
		posterior cingulate	